

Aesthetic Surgery Journal

<http://aes.sagepub.com/>

Complications Following Injection of Soft-Tissue Fillers

Cemile Nurdan Ozturk, Yumeng Li, Rebecca Tung, Lydia Parker, Melissa Peck Piliang and James E. Zins
Aesthetic Surgery Journal 2013 33: 862 originally published online 3 July 2013
DOI: 10.1177/1090820X13493638

The online version of this article can be found at:
<http://aes.sagepub.com/content/33/6/862>

Published by:



<http://www.sagepublications.com>

On behalf of:



[American Society for Aesthetic Plastic Surgery](http://www.asap-society.org)

Additional services and information for *Aesthetic Surgery Journal* can be found at:

Email Alerts: <http://aes.sagepub.com/cgi/alerts>

Subscriptions: <http://aes.sagepub.com/subscriptions>

Reprints: <http://www.sagepub.com/journalsReprints.nav>

Permissions: <http://www.sagepub.com/journalsPermissions.nav>

>> [Version of Record](#) - Aug 1, 2013

[OnlineFirst Version of Record](#) - Jul 3, 2013

[What is This?](#)



Review Article

Complications Following Injection of Soft-Tissue Fillers

Aesthetic Surgery Journal
33(6) 862–877
© 2013 The American Society for
Aesthetic Plastic Surgery, Inc.
Reprints and permission:
[http://www.sagepub.com/
journalsPermissions.nav](http://www.sagepub.com/journalsPermissions.nav)
DOI: 10.1177/1090820X13493638
www.aestheticsurgeryjournal.com

Cemile Nurdan Ozturk, MD; Yumeng Li, BS; Rebecca Tung, MD;
Lydia Parker, MD; Melissa Peck Piliang, MD; and James E. Zins, MD

Abstract

Background: Soft-tissue filler injection is a very common procedure in the United States. Although the safety profile is favorable, adverse events (AE) can occur, ranging from mild to severe in intensity.

Objectives: The authors performed a literature search to identify the facial sites most prone to severe complications. They review the course of these complications and discuss preventive measures.

Methods: The National Library of Medicine, the Cochrane Library, and Ovid MEDLINE were searched, and relevant articles (published through August 2012) were retrieved based on prespecified inclusion criteria. The complications reviewed were limited to “severe” events, such as soft-tissue necrosis, filler embolization, visual impairment, and anaphylaxis. The filler materials included were those approved by the US Food and Drug Administration at the time of this study.

Results: Forty-one articles, representing 61 patients with severe complications, were identified. Data collected from these case reports included filler type, injection site, complication site, symptom interval, symptom of complication, time to therapy, modality of treatment, and outcome. The most common injection site for necrosis was the nose (33.3%), followed by the nasolabial fold (31.2%). Blindness was most often associated with injection of the glabella (50%). An estimated incidence of 0.0001% for developing a severe complication was calculated by reviewing society-based filler data and case reports within same time period.

Conclusions: Although soft-tissue fillers are a popular choice for minimally invasive rejuvenation of the face, physicians should be aware of the serious potential adverse effects, recognize their presentations, and have appropriate treatments readily available.

Keywords

filler, injectable, complication, blindness, necrosis, cosmetic medicine, literature review

Accepted for publication November 26, 2012.

The use of soft-tissue fillers for cosmetic purposes has increased dramatically in recent years. According to the 2012 statistics published by the American Society for Aesthetic Plastic Surgery (ASAPS), fillers are now the second most common minimally invasive procedure performed among plastic surgeons, behind botulinum toxin injections.¹ The trend is similar in dermatology practice. Data from the American Society for Dermatologic Surgery (ASDS) demonstrate that injectables are also the second most common minimally invasive procedure performed by dermatologists (also following botulinum toxin).² The popularity of fillers is attributable to their ease of application, significant beneficial effect on appearance, and low rate of complications.

Dr Ozturk is an Aesthetic Surgery Fellow and Dr Zins is Chairman of the Department of Plastic Surgery at the Cleveland Clinic, Cleveland, Ohio. Dr Piliang is a staff physician in the Departments of Dermatology and Anatomic Pathology at the Cleveland Clinic, Cleveland, Ohio. Ms Li is a medical student at the Cleveland Clinic Lerner College of Medicine, Cleveland, Ohio. Dr Tung is Chairman of the Division of Dermatology at Loyola University, Stritch School of Medicine, Maywood, Illinois. Dr Parker is a Clinical Instructor in the Department of Dermatology at Case Western Reserve University, School of Medicine, Cleveland, Ohio.

Corresponding Author:

Dr James E. Zins, Department of Plastic Surgery, Cleveland Clinic, 9500 Euclid Ave, Desk A60, Cleveland, OH 44195, USA.
Email: zinsj@ccf.org

Although soft-tissue fillers have a very favorable safety profile, adverse events (AE) can occur. Minimal and self-limited complications are relatively common and perhaps would be more appropriately termed *adverse sequelae* rather than true complications. Such events include ecchymosis, swelling, and erythema. More significant yet self-limited complications also have occurred, including overcorrection, irregularities, filler visibility, Tyndall effect, and granuloma formation. Complications of greater severity also have been reported, such as visual impairment, skin necrosis, and anaphylaxis. The goal of the present review is to highlight the more serious complications, identify the areas and techniques most prone to complications, suggest means for minimizing complications, and discuss effective methods of treatment.

METHODS

A literature search was performed to gather information on severe complications following injection of soft-tissue fillers from reports published through August 2012. The databases of the National Library of Medicine (PubMed), the Cochrane Library, and Ovid MEDLINE were searched using the following Boolean string: (anaphylaxis OR blindness OR necrosis OR embolization OR scar OR complication) AND (filler OR injectable). Additional searching was done using the phrases *soft-tissue filler complications*, *dermal filler complications*, and *injectable complications*. The references cited in selected articles also were reviewed to potentially identify additional reports that matched the criteria. The search was limited to the English-language literature and to the head and neck region.

Reports of “severe” complications following use of injectables were selected for this review; these included soft-tissue necrosis, filler embolization resulting in impending necrosis, blindness, partial loss of vision, transient loss of vision, and anaphylaxis. Cases of visual impairment with concomitant necrosis were counted only once, in the vision loss subgroup. The only filler materials included were those that had been approved by the US Food and Drug Administration (FDA) at the time of the review. These materials were collagen, hyaluronic acid (HA), polymethylmethacrylate (PMMA) suspended in collagen, calcium hydroxylapatite (CaHa), poly-L-lactic acid (PLLA), and injectable dermal matrix. Autologous fat, liquid silicone, and other non-FDA-approved substances were excluded.

RESULTS

A total of 41 reports representing 61 patients with severe complications were identified. A summary of the cases, therapies, and outcomes is presented in Table 1. The complications were classified into 3 groups: (1) soft-tissue necrosis or impending necrosis as a result of filler embolization, (2) visual impairment, and (3) anaphylaxis. Figure 1 shows the distribution of complications by injection site.

Of the 61 cases, the injection site most commonly associated with complications was the nose (32.8%; n = 20), followed by the glabella (26.2%; n = 16) and the nasolabial fold (NLF) (26.2%; n = 16). In 4 cases, the injection site was not specified.^{3,4} The distribution of complications according to filler type is shown in Figure 2. Hyaluronic acid was the most common filler implicated in necrotic complications, and collagen was the most common filler resulting in visual impairment. Filler type was not reported for 2 cases.^{5,6} One case of anaphylactic shock occurred after the eighth injection session of PMMA.⁷ However, neither the specific clinical presentation nor the outcome was described.

Soft-Tissue Necrosis and Impending Necrosis

There were 39 cases of significant soft-tissue loss and 9 cases of “impending necrosis” (Table 1). The responsible substances were HA, PMMA, collagen, and CaHa. Common injection sites for these complications were the nose (33.3%; n = 16),^{3,4,8-15} NLF (31.2%; n = 15),^{4,8,13,16-23} and glabella (20.8%; n = 10).^{17,24-30} Other sites were the cheeks and lips (in 1 and 2 cases, respectively).³¹⁻³³ In 4 cases (8.3%), the site of injection was not reported.^{3,4} Of the 16 nasal injections, 5 were in the nasal tip,^{3,8-10,13} 1 was in the lateral nose,⁴ 3 were in the dorsum,¹⁰ and 2 were in the dorsum as well as the tip.^{11,14} One patient had multiple injections to the nose, forehead, and glabella.¹⁴ For the other 4 cases, the specific nasal location was not reported.^{3,9,12,15} Details of injection technique and needle size were not described for any case of necrosis.

The symptom most often associated with intravascular injection was immediate pain upon administration of the product. Other acute symptoms included blanching, duskiness, and ecchymosis. In several cases, no signs were noted at the time of injection, and delayed compression of vessels by product was proposed as a possible mechanism of injury.^{20,21,33}

The affected sites showed additional signs of vascular compromise within 1 to 2 days, including erythema, white or violaceous discoloration, edema, bruising, and ongoing pain. In patients with “impending necrosis,” the symptoms and signs improved, sometimes associated with early intervention, and resolved without sequelae.

When soft-tissue loss occurred, slough, ulceration, and eschar developed within 3 to 7 days after injection. The tissue loss occurred directly at the injection site in 46.2% of cases (n = 18) and at the site nourished by the compromised vessel in 28.2% (n = 11). The latter included necrosis developing at the forehead and nose after glabellar injection^{26,27,30} and necrosis developing at the nasal ala and lip after NLF injection.^{4,8,13,16,18,23} In 10 cases (25.6%), the data were insufficient to make a correlation between treatment site and complication site.

A variety of treatments were used, including hyaluronidase, nitroglycerin paste, warm compresses, intravenous

(text continues on p. 868)

Table 1. Literature Summary: Reports of Severe Complications After Use of Injectable Fillers

Reference and No. of Cases	Complication	Type of Filler	Injection Site	Symptom Interval, Complaints, Location	Time to Therapy, Treatment Utilized	Outcome	Injecting Physician	Country
Hanke et al, 1991 ²⁹ 1 case	Necrosis	Collagen	Glabella	NR	NR	NR	Dermatologist	United States
Monheit, 1998 ¹² 1 case	Necrosis	Collagen	Nose	NR	NR	NR	NR	United States
Schanz et al, 2002 ²⁷ 1 case	Necrosis	HA	Glabella	Minutes: reticular pattern at injection site and nose; no pain 10 days: ulceration at injection site, glabella, and nose	Immediate: low-molecular-weight heparin 5000 IE daily (1 wk)	Complete recovery	Dermatologist	Germany
Friedman et al, 2002 ²⁴ 2 cases	Necrosis	HA	Glabella	NR	NR	NR	NR	NR
Lowe, 2003 ³³ 1 case	Impending necrosis	HA	Lip	Venous occlusion; persistent edema at injection site	NR	NR	Dermatologist	United Kingdom
Bellman, 2006 ¹⁹ 1 case	Impending necrosis	HA	NLF	Immediate: bruising; edema at injection site 2 days: sensitivity; pustules; reticulated bruising; edema at injection site and nasal tip	2 days: dynacin 100 mg PO and prednisone 20 mg PO 4 days: hydrogen peroxide, mupirocin ointment, and warm compress	Complete recovery	Dermatologist	United States
Narins et al, 2006 ³² 1 case	Necrosis	HA	Lip	Immediate: bleeding and bruising Later: necrosis of left lower lip	2 weeks: PO corticosteroid and antibiotics; secondary intention	Complete recovery	NR	United States
Steinsapir and Steinsapir, 2006 ²⁵ 1 case	Necrosis	HA	Glabella	NR	NR	Scarring	Ophthalmologist	United States
Gladstone and Cohen, 2007 ²⁶ 1 case	Necrosis	HA	Glabella	Necrosis at forehead	NR	NR	Dermatologist	United States
Hirsch et al, 2007 ²¹ 1 case	Impending necrosis	HA	NLF	2 days: pain and erythema at injection site	2 days: aspirin 325 mg, nitroglycerin paste, and warm compress 3 days: hyaluronidase 30 U	Complete recovery	Dermatologist	United States
Hirsch et al, 2007 ²² 1 case	Impending necrosis	HA	NLF	6 hours: erythema and discoloration at injection site	6 hours: aspirin 325 mg, nitroglycerin paste, warm compress, and hyaluronidase 30 U	Complete recovery	Dermatologist	United States
Salles et al, 2008 ¹³ 3 cases	All 3 cases: necrosis	All 3 cases: PMMA	Case 1: nose (tip) Case 2: NLF and nose Case 3: NLF	Case 1: 7 days: hyperemia, swelling, and necrosis of ala Case 2: Immediate: pain Later: necrosis of ala and upper lip Case 3: necrosis of ala upper and lower lateral lip	All 3 cases: NR	All 3 cases: scarring	Case 1: plastic surgeon Case 2: dermatologist Case 3: plastic surgeon	Brazil

(continued)

Table 1. (continued)

Reference and No. of Cases	Complication	Type of Filler	Injection Site	Symptom Interval, Complaints, Location	Time to Therapy, Treatment Utilized	Outcome	Injecting Physician	Country
Inoue et al, 2008 ¹⁶ 1 case	Necrosis	Collagen	NLF	Immediate: pain at left side of face First hours: reddish discoloration 6 days: necrosis of nasal ala	6 days: IV alprostadil 120 µg/d for 2 wk; surgical debridement	Scarring; reconstruction with skin graft	Plastic surgeon	Japan
Grunebaum et al, 2009 ⁸ 3 cases	Case 1: necrosis Case 2: necrosis Case 3: impending necrosis	All 3 cases: HA	Case 1: NLF Case 2: NLF Case 3: nose (tip)	Case 1: 1 day: skin irritation; numbness 3 days: necrosis of nasal ala Case 2: First hours: pain; dusky erythema 12 hours: necrosis of nasal ala Case 3: Immediate: erythema of nose	Case 1: 3 days: Bacitracin; secondary intention Case 2: Immediate: hydrocolloid dressing; hyaluronidase 40 U Case 3: Immediate: nitropaste (for 1 wk) and hyaluronidase (3 times)	Case 1: complete recovery Case 2: scarring Case 3: complete recovery	NR	United States
Georgescu et al, 2009 ¹⁷ 2 cases	Both cases: necrosis	Both cases: CaHA	Case 1: glabella Case 2: NLF	Case 1: Hours: pain and bruising at injection site 2 days: necrosis at glabella Case 2: Same day: pain and swelling over fold; necrosis; ecchymosis	Case 1: 2 days: PO corticosteroid; nitroglycerin paste (1 wk) 4 months: microdermabrasion Case 2: Same day: PO antibiotics and steroids Months: Microdermabrasion and hydrocortisone ointment	Both cases: complete recovery	NR	United States
Winslow, 2009 ¹⁵ 1 case	Necrosis	CaHA	Nose	Immediate: blanching Days: bluish discoloration; ischemic purpura; edema; mild epidermolysis of nose	Nitroglycerin paste (timing not specified)	Complete recovery	Plastic surgeon	United States
Bachmann et al, 2009 ²⁸ 2 cases	Both cases: necrosis	Both cases: HA	Both cases: glabella	Case 1: 1 day: erythema; inflammation; abscess formation at injection site Case 2: Immediate: pain 1 day: erythema and edema 5 days: discoloration abscess 3 weeks: ulceration	NR	Both cases: recovery with scarring	NR	Germany
Humphrey et al, 2009 ⁹ 2 cases	Both cases: impending necrosis	Both cases: HA	Both cases: nose (tip)	Case 1: 12 hours: blanching and discoloration at injection site Case 2: 1 week: discoloration and numbness at cold temperature	Case 1: 12 hours: nitroglycerin paste (1 wk), warm compress, and hyaluronidase (15 U; 3 times) Case 2: hyaluronidase (15 U)	Both cases: partial recovery	Otolaryngologist	United States
Burt et al, 2010 ¹⁸ 1 case	Necrosis	HA	NLF	1 day: pain and poor perfusion 3 days: sloughing and ulceration of nasal ala	NR	Complete recovery	Plastic surgeon	United States

(continued)

Table 1. (continued)

Reference and No. of Cases	Complication	Type of Filler	Injection Site	Symptom Interval, Complaints, Location	Time to Therapy, Treatment Utilized	Outcome	Injecting Physician	Country
Kassir et al, 2011 ³¹ 1 case	Necrosis	HA	Cheek	First hours: pain; bluish discoloration 5 days: slough and eschar of right cheek	5 days: massage; IM, topical, and PO antibiotics; Valtrex; silicone gel	Scarring	Plastic surgeon	United States
Kim et al, 2011 ¹⁰ 4 cases	All 4 cases: necrosis	All 4 cases: HA	Case 1: nose (tip) Cases 2, 3, and 4: nose (dorsum)	All 4 cases: Immediate: pain Later: reticular skin discoloration and necrosis of nasal dorsum and tip	Case 1: 1 day: hyaluronidase Case 2: 1 day: hyaluronidase	All 4 cases: scarring	Plastic surgeon	Korea
Park et al, 2011 ⁴ 3 cases	All 3 cases: necrosis	All 3 cases: HA	Case 1: nose (sidewall) Case 2: NR Case 3: NLF	Case 1: NR Case 2: necrosis of mentum Case 3: necrosis of ala	Case 1: 3 months: PO antibiotics Case 2: 2 months: surgical excision Case 3: 1 week: oral antibiotics	NR	NR	Korea
Kim et al, 2011 ¹¹ 1 case	Necrosis	HA	Nose (dorsum and tip)	Hours: swelling and discoloration at injection site Days: dark brown and purple discoloration at nasal tip	1 day: filler removal (puncture) Days: IV alprostadil and topical antibiotics	Recovery with minimal scarring	Plastic surgeon	Korea
Dayan et al, 2011 ²⁰ 3 cases	Cases 1 and 2: impending necrosis Case 3: necrosis	All 3 cases: CaHA	Case 1: NLF, infra-orbital region Case 2: NLF Case 3: NLF	Case 1: Immediate: blanching over left cheek, NLF, and left upper lip 2 days: edema and erythema of left lower face; reticulated vascular congestion of upper lip and left buccal mucosa Case 2: 1 day: tenderness; erythema; drainage at fold Case 3: 1 day: edema; erythema; bruising at fold and malar region Later: ulceration at fold	Case 1: Immediate: nitroglycerin paste (for 5 days) 2 days: hyaluronidase 150 U; methylprednisone PO; aspirin 325 mg/d (2 wk); topical oxygen infusion cream Case 2: 1 day: Nitroglycerin paste; antibiotic ointment; hyaluronidase 20 U; aspirin 325 mg/d; PO antibiotics 4 days: Hyaluronidase 15 U; topical oxygen infusion cream Case 3: Days: IV and PO antibiotics; PO valacyclovir; topical steroid 4 weeks: hyaluronidase 40 U; nitroglycerin paste; aspirin 325 mg/d, antacids; topical oxygen infusion cream	Cases 1 and 2: complete recovery Case 3: NR	NR	United States
Park et al, 2011 ²³ 1 case	Necrosis	HA	NLF	1 hour: erythema on central face 2 days: Necrosis at nasal tip with pain and tenderness	1 day: hyaluronidase 20 U (once) and warm compress 2 days: Bacitracin ointment	Complete recovery	Dermatologist	Korea

(continued)

Table 1. (continued)

Reference and No. of Cases	Complication	Type of Filler	Injection Site	Symptom Interval, Complaints, Location	Time to Therapy, Treatment Utilized	Outcome	Injecting Physician	Country
Sung et al, 2011 ¹⁴ 2 cases	Both cases: necrosis	Both cases: HA	Case 1: nose, forehead, glabella Case 2: nose (tip and dorsum)	Case 1: 1 day: tenderness and erythema 5 days: necrosis of nasal tip Case 2: 1 day: erythema and pain 5 days: necrosis of nasal tip and dorsum	Case 1: Immediate: IV antibiotics; hydrocolloid dressing 3 days: adipose-derived stem cells Case 2: Immediate: hyaluronidase 1000 U; steroid injection 5 days: IV antibiotics; debridement 11 days: adipose-derived stem cells	Both cases: recovery with scarring	NR	Korea
Nettar and Maas, 2012 ²⁰ 1 case	Necrosis	HA	Glabella	Immediate: blanching 1 day: discoloration; bruising at injection site 1 week: necrosis of forehead	1 day: amica cream and ice compress 1 week: surgical debridement	NR	Plastic surgeon	United States
de Melo Carpaneda and Carpaneda, 2012 ³ 5 cases	All 5 cases: necrosis	All 5 cases: PMMA	Case 1: nose (tip) Case 2: nose Cases 3, 4, and 5: NR	All 5 cases: Immediate: intense pain 1-2 days: white to violet discoloration Later: necrosis Case 1: necrosis of nasal tip Case 2: necrosis of nasal ala and dorsum Case 3: necrosis of nasal ala and tip and lips	NR	Cases 1, 3, 4, and 5: NR Case 2: scarring	NR	Brazil
Castillo, 1989 ³⁴ 1 case	Blindness	Collagen	Glabella, cheek	NR	NR	NR	NR	United States
Hanke, 1998 ⁴³ 1 case	Blindness	Collagen	Glabella	NR	NR	NR	Dermatologist	United States
Apte et al, 2003 ³⁶ 1 case	Visual impairment	Injectable dermal matrix	Forehead	10 minutes: nausea; diaphoresis; pain in left eye; blurred vision	NR	Vision loss with light perception	NR	United States
Silva and Curi, 2004 ⁴⁰ 1 case	Blindness	PMMA	Glabella	Immediate: severe pain and visual loss in right eye	NR	Blindness and total ophthalmoplegia	NR	Brazil
Kubota and Hirose, 2005 ³⁸ 1 case	Blindness	PMMA	Nose (dorsum)	15 minutes: pain and visual loss in right eye	NR	Blindness	Plastic surgeon	Japan
Peter and Mennel, 2006 ³⁵ 1 case	Visual impairment	HA	Glabella, cheeks	1 minute: partial loss of vision in inferior right visual field	Immediate: acetazolamide	Complete recovery	NR	United States
Kang et al, 2007 ⁶ 1 case	Visual loss and necrosis	NR	Glabella	Immediate visual loss; necrosis of glabellar region	NR	NR	NR	Korea

(continued)

Table 1. (continued)

Reference and No. of Cases	Complication	Type of Filler	Injection Site	Symptom Interval, Complaints, Location	Time to Therapy, Treatment Utilized	Outcome	Injecting Physician	Country
Hwang et al, 2008 ⁵ 1 case	Visual loss	NR	Glabella, nose, periorbital	Immediate: visual loss in left eye; erythematous color change at site of injection	Acetazolamide (1 wk) and methylprednisolone (3 d)	Partial recovery with 20/200 visual acuity	NR	Korea
Kwon et al, 2010 ⁴² 1 case	Blindness, necrosis, stroke lesion	Collagen	Nose (septum)	Immediate: visual loss in left eye; headache Later: reticular violet discoloration	Antiplatelet agent and calcium channel blocker	Blindness	NR	Korea
Sung et al, 2010 ⁴¹ 1 case	Visual loss, necrosis	CaHa	Nose (dorsum)	Immediate: pain in right eye; ptosis; ophthalmoplegia Later: reddish reticular pattern in right eyelid	8 hours: IV antibiotics, topical steroids, and PO corticosteroids	Complete recovery with fixed dilated pupil; minimal scarring	Dermatologist	Korea
Kim et al, 2011 ³⁷ 1 case	Blindness, necrosis	HA	Nose (tip)	Immediate: visual loss in left eye; pain in left upper face; ophthalmoplegia 2 days: violaceous, ulcerative patches	2 days: IV methylprednisolone; aspirin 100 mg PO	Blindness; recovery from ophthalmoplegia	Plastic surgeon	Korea
Roberts and Arthurs, 2012 ³⁹ 1 case	Blindness	PLLA	Periorbital region	Immediate: visual loss and pain in left eye 1 day: nausea; ophthalmoplegia; ptosis	NR	Blindness; recovery from ophthalmoplegia	NR	Canada
Lemperle et al, 2003 ⁷ 1 case	Anaphylactic shock	PMMA	NLF	NR	NR	NR	NR	Italy

Abbreviations: CaHa, calcium hydroxylapatite; HA, hyaluronic acid; IM, intramuscular; IV, intravenous; NLF, nasolabial fold; NR, not reported; PLLA, poly-L-lactic acid; PMMA, polymethylmethacrylate; PO, per oral.

(IV) prostaglandins, topical and oral antibiotics, topical and oral corticosteroids, low-molecular-weight heparin, topical oxygen, massage, hydrocolloid dressings, and eventual surgical treatment.* Adipose-derived stem cells were used in 2 cases of nasal tip necrosis.¹⁴ The treatment choice varied according to when the patient was examined by the reporting physician. Because the case reports provided too little detail and the number of cases was small, it was not possible to establish a correlation between treatment initiation and outcome. Of the 39 cases of soft-tissue loss, 11 (28.2%) reportedly healed completely, with no or minimal scarring.^{8,11,15-18,20,23,27,32} Fifteen patients (38.5%) had visible scars after complete healing.^{8,10,13,25,28,31} For the remaining 13 cases (33.3%), outcomes were not reported.

Visual Impairment

There were 12 cases of visual impairment resulting from filler embolism to the ophthalmic vasculature (Table 1).

*References 4, 8, 9, 11, 12, 15-17, 20, 23, 27, 31, 32.

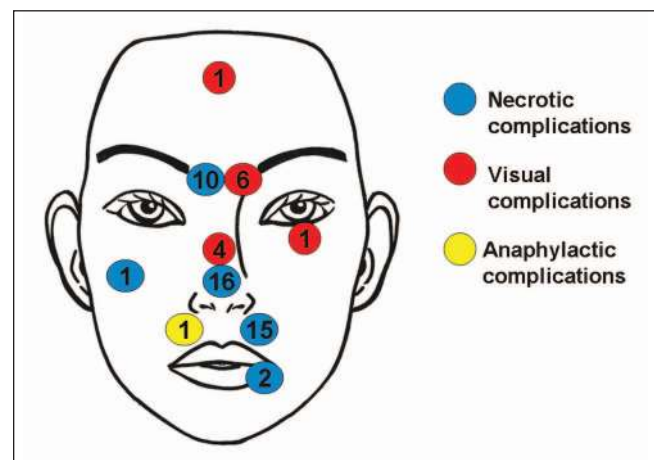


Figure 1. Distribution of complications according to injection site and type (necrotic, visual, anaphylactic). Numbers in blue, red, and yellow circles represent the number of cases who had necrotic, visual, and anaphylactic complications, respectively.

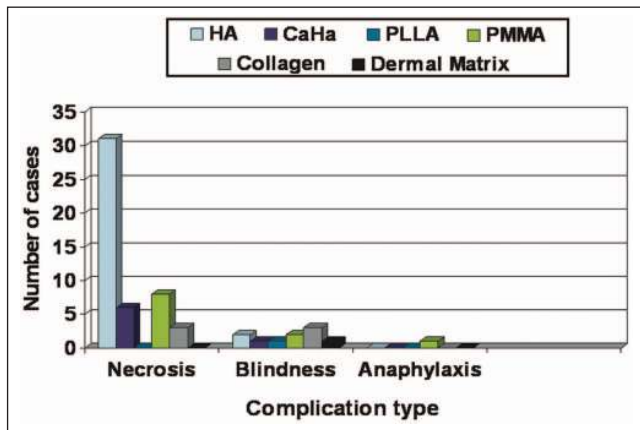


Figure 2. Distribution of severe complications according to type of filler. CaHa, calcium hydroxylapatite; HA, hyaluronic acid; PLLA, poly-L-lactic acid; PMMA, polymethylmethacrylate.

The injected substances were HA, PMMA, injectable dermal matrix, collagen, PLLA, and CaHa. Specific details regarding injection technique and needle type were not described in any of these reports. The glabella was the most common site yielding visual complications (50%; $n = 6$), followed by the nose (33.3%; $n = 4$), forehead (8.3%; $n = 1$), and periorbital region (8.3%; $n = 1$). In 3 patients who had injection of the glabella, injections also were made in the nose, cheeks, and periorbital area.^{5,34,35}

In all 12 cases, the signs and symptoms of visual loss developed within minutes of the filler injection. Visual impairment was almost always accompanied by pain in the affected eye.³⁶⁻⁴¹ Other immediate symptoms included diplopia, nausea, headache, ophthalmoplegia, and ptosis.^{36,37,39,41,42} In 4 cases, a violaceous reticular discoloration was evident several days after the injection, which was followed shortly by soft-tissue necrosis in the glabella and nose.^{6,37,41,42} One patient experienced ischemic stroke in addition to vision loss.⁴² Various treatment attempts were used, including diuretic agents, antiplatelet agents, systemic steroids, and aspirin.^{5,35,37,41,42} In 7 cases, no information on treatment was provided.^{6,34,36,38-40,43} Only 2 of the 12 patients (16.7%) had complete recovery of vision,^{35,41} and 1 (8.3%) had partial recovery.⁵ Six of the 12 cases (50%) resulted in permanent complete blindness.^{36-40,42} In 3 cases (25%), the outcome was not clear.^{6,34,43}

DISCUSSION

The increasing demand for soft-tissue augmentation, using a wide variety of fillers, has been documented repeatedly. Since the introduction of collagen as a standard injectable material in the 1980s, a number of filler materials have been manufactured and approved by the FDA. All FDA efficacy testing of newer fillers has been based on the collagen prototype, using split-face studies.⁴⁴⁻⁴⁸ In other words, new fillers

merely had to meet or exceed the safety and efficacy standards of collagen products when collagen was injected into 1 NLF and the filler tested in the contralateral fold. Direct comparisons were then made between the duration of soft-tissue correction and the complications that occurred. Since 2010, collagen filler products have not been available in the United States, with the exception of bovine collagen, used as a carrier for PMMA microspheres.

The FDA has approved a variety of different filler materials, each with a distinct composition, injection profile, and duration of effect. Many of them are in use off-label at the discretion of the physician. Currently, HA is the most commonly used injectable, followed by CaHa and PLLA.¹ Therefore, it is not surprising that HA products are implicated most frequently in severe complications. These fillers also have different mechanisms of action and different periods of persistence in tissue. Among the temporary materials, HA remains in the tissue for 4 to 12 months, whereas collagen typically lasts only 2 to 4 months. Recent studies have shown that reinjection 4 to 5 months following initial treatment significantly increases the efficacy of HA products.⁴⁹⁻⁵¹ CaHa and PLLA are considered semipermanent fillers and may last 1 to 2 years in tissue. The only FDA-approved permanent filler is PMMA. Although the collagen carrier of this filler resorbs over time, the microspheres do not degrade, resorb, or dissolve, yielding permanent correction of wrinkles.

Even though soft-tissue fillers are generally safe, undesirable effects can occur with any type of filler. Adverse effects may result from injection techniques (eg, overcorrection, irregularities, Tyndall effect, intravascular injection) or can be host-initiated local events. Some of these effects may resolve with time, but others will require intervention based on severity and/or the type of filler used. Visual impairment, soft-tissue necrosis, permanent scarring, and anaphylaxis are rare but severe events.

Determining the Incidence of Complications

The lack of an organized database, combined with the fact that the injections generally are not performed in hospitals or outpatient facilities, makes it very difficult to obtain accurate data on complications, although several attempts have been made to estimate the number. Hanke et al²⁹ published data pertaining to a 7-year period (1982-1989) and reported an average annual incidence of 0.09% for necrosis and abscess after collagen treatments. In 2002, based on a review of manufacturer-supplied data, Friedman et al²⁴ examined the safety profile of HA injections performed outside the United States. The overall incidence of AE was reportedly 0.15% in 1999 and 0.06% in 2000. Narins et al³² used information from spontaneous drug AE reporting (SAER) systems to identify the more severe HA-related complications and reviewed the published cases in the United States in 2004. They estimated the incidence to be less than 0.001%.³² Current statistics on fillers and associated complications can be gathered readily from company-based data as well as national societies.

Considering the widespread use of fillers by many specialties, the large variety of brands worldwide, and unreliable methods of data collection, determining an accurate incidence of complications is a challenging task. When combining procedural data from ASAPS and ASDS statistics from 2010 to 2011, the number of filler treatments performed by plastic surgeons and dermatologists totaled approximately 4 658 982 for the 2-year period.^{1,2} In the same timeframe, the number of cases of severe complications in the United States reported by the same specialties was only 5,^{18,20,31} yielding an estimated incidence of 0.0001%. Until a database is established by our professional societies, which allows for prospective data entry, the true incidence of complications will remain unknown.

Treatment of Mild, Moderate, and Self-Limited Complications

A review of the Manufacturer and User Facility Device Experience (MAUDE) database from 2003 to 2008 demonstrated that the most common AE associated with fillers were swelling, erythema, and inflammatory reactions such as granulomas and nodules.⁵² Other mild to moderate complications included hypersensitivity, infection, bruising, Tyndall effect, pain, blisters, beading of filler under skin, numbness, and migration.

Swelling and ecchymosis may develop at the time of injection and usually resolve spontaneously.^{32,53-55} Erythema also is commonly transient but, on occasion, permanent telangiectasias may occur at the injection site. If this happens, treatment with intense pulsed light therapy or pulsed dye laser can be initiated.^{56,57} Nodules and erythema that persist beyond the first few days of treatment may be signs of inflammation.^{53,57,58} In these cases, massage and administration of hyaluronidase for HA products have proven helpful.⁵⁸ After infection is ruled out, intralesional or topical corticosteroids also may be used.^{53,57}

Lumps or beading usually appear shortly after treatment in the form of well-confined palpable lesions, which can result from injection in areas of thin soft-tissue coverage (eg, eyelids, nasojugal region, lips), injection of too much material, clumping of filler, or dislocation by movement of muscles.^{56,57,59,60} Common sites for irregularities and lumps include the lips and the perioral area. The lips are an area of high mobility and thin mucosa. Once irregularities in the mucosa of the lips occur, they are difficult to correct if semipermanent fillers have been injected. Therefore, the use of semipermanent fillers in this area is discouraged^{61,62} (Figure 3). The tear trough and periorbital regions also are considered high risk and are prone to display irregularities if injected superficially.^{54,63,64} Measures to avoid visibility of the implanted material include firm massage and meticulous placement of filler in the deep supraperiosteal plane.^{58,65} Relatively short-term fillers such as HA products are preferable for these high-risk regions. An additional benefit of using HA in these areas is that irregularities can be reversed with

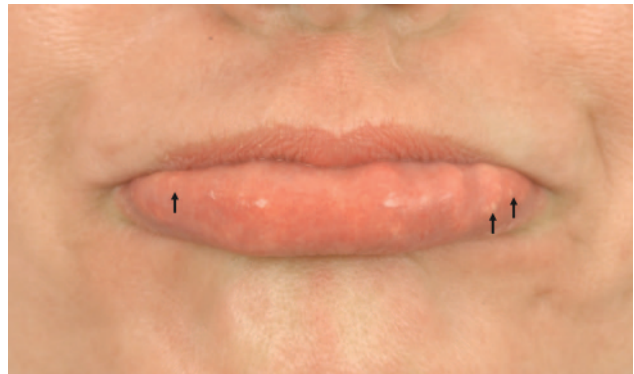


Figure 3. This 47-year-old woman, who had been injected with calcium hydroxylapatite at another clinic, presented 4 months later with white nodules along the lower lip. The granules were palpable and visible (arrows) just under the mucosa of the lower lip. The patient refused surgical excision.

hyaluronidase (15-300 U). Semipermanent fillers such as CaHa and PLLA have the advantage of being longer lasting than HA; however, with this benefit comes a disadvantage. If overcorrection occurs, irregularity and nodule formation can develop; these problems are more persistent and difficult to treat. To prevent technique-related complications, injection should be in the subdermal plane, bolus injection should be avoided, and injection sites should be massaged after injection.^{66,67} Treatments for semipermanent fillers include direct excision of the filler, needle disruption and unroofing of lumps, and waiting for the product to absorb.⁶⁶⁻⁷⁰ Lumps caused by PLLA or PMMA respond well to intralesional steroid injections, but steroids are less effective for CaHa.⁵⁶

True granulomas appear late, after weeks or months, and respond well to intralesional steroids^{55-57,60,65} or incision and drainage. The reported rate of granuloma is 0.01% to 1%.^{48,56} Recently, there has been discussion on the role of biofilms in causing delayed nodule formation.^{32,55,71-75} Biofilms are accumulations of microorganisms within a self-developed matrix, which are irreversibly adherent to one another and to a variety of surfaces.^{75,76} All fillers, especially longer-lasting products, are potential surfaces for biofilm formation. Because their growth rate is slow, biofilms usually are not identifiable by culture. They may present as sterile abscesses or cause a chronic inflammatory response.^{55,75,77-79} Infections resulting from biofilms are notoriously difficult to treat because of their slow bacterial metabolism and their secretion of a protective matrix.⁷⁷ Hyaluronidase has been shown to help break down the matrix, thereby decreasing the biofilm mass.⁸⁰ Dayan et al⁷⁵ reported successful treatment of resistant inflammatory reactions with hyaluronidase regardless of the filler used. Other treatment options for biofilms are prolonged use of antibiotics, administration of intralesional 5-fluorouracil,

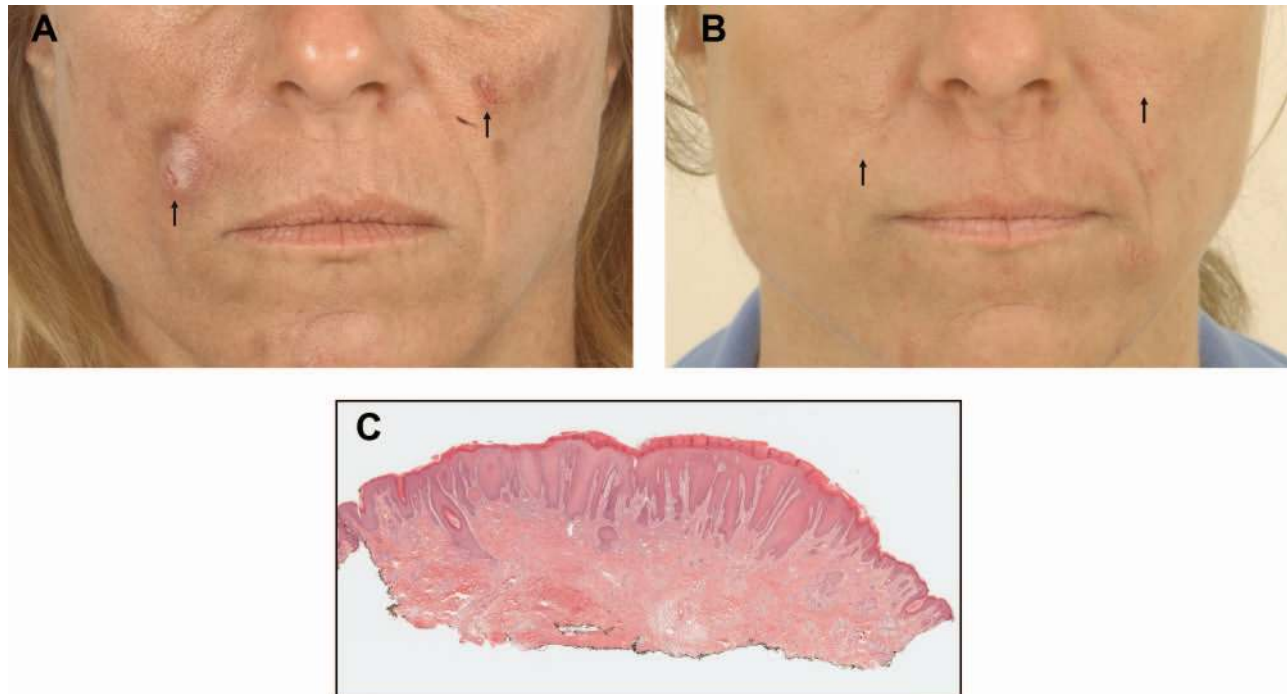


Figure 4. (A) Two weeks after injection of collagen to the nasolabial folds, this 42-year-old woman complained of nodules and ulceration, which persisted for another 2 weeks. She had multiple erythematous and partially ulcerated lesions (arrows) on other areas of the face, which suggested factitious disorder. She was treated with oral antibiotics and steroids. (B) Ten months after excision of the ulcerated lesion and granuloma on the right nasolabial fold (left arrow). The rest of the lesions healed by secondary intention (right arrow). (C) Pathologic findings of the excised area were consistent with prurigo nodularis (Picker nodule).

and intralesional laser therapy with a 532-nm or 808-nm laser.^{77,81-83} With respect to antimicrobials, 2-drug therapy with a quinolone and third-generation macrolide has been recommended.^{55,77} To prevent biofilm formation or other soft-tissue infections, care should be taken to avoid any contamination during implantation. A sterile technique should be used when reconstituting or diluting the product, the injection site should be prepared with topical antiseptics, injection to infected areas should be avoided, and makeup and other potential contaminants on the skin should be removed before injection.^{67,74,84} Moreover, the following should be avoided: injection of high-volume bolus material, breaching of mucosa, and injection through previous filler.^{75,76} However, it is important to note that cases of recurrent, unexplained infections can be the result of other pathology. Factitious ulceration also should be considered in this setting (Figure 4).

Hypersensitivity to fillers may trigger angioedema or anaphylactic reactions.^{56,63,74,85} Delayed hypersensitivity reactions are usually self-limited systemic events that resolve without any sequelae but, depending on the presentation, oral steroid treatment may be required. Although collagen itself is no longer available, other collagen-containing products (such as PMMA in collagen suspension) require skin testing prior to administration.

Mild to moderate complications are usually self-limited. Consensus treatments for complications that fail to resolve within several weeks include hyaluronidase injection, intralesional steroids, and light-based therapies. Systemic steroids, systemic antibiotics, and/or surgical excision may be required depending on the extent of the problem. An algorithm for the treatment of mild to moderate complications is presented in Figure 5.

Treatment and Prevention of Severe Complications

Vascular-related events are the complications most likely to result in permanent sequelae. They can occur from intravascular embolism of injected material, direct needle injury to vessels, or external compression of vessels by surrounding filler[†] (Figure 6). Inadvertent injections of the angular, dorsal nasal, or supratrochlear artery are most likely to lead to an ischemic response that results in necrosis.^{31,54,65}

Appropriate treatment should be started immediately upon suspicion of vascular compromise. Injection should

[†]References 10, 16, 18, 26, 27, 31, 53, 56.

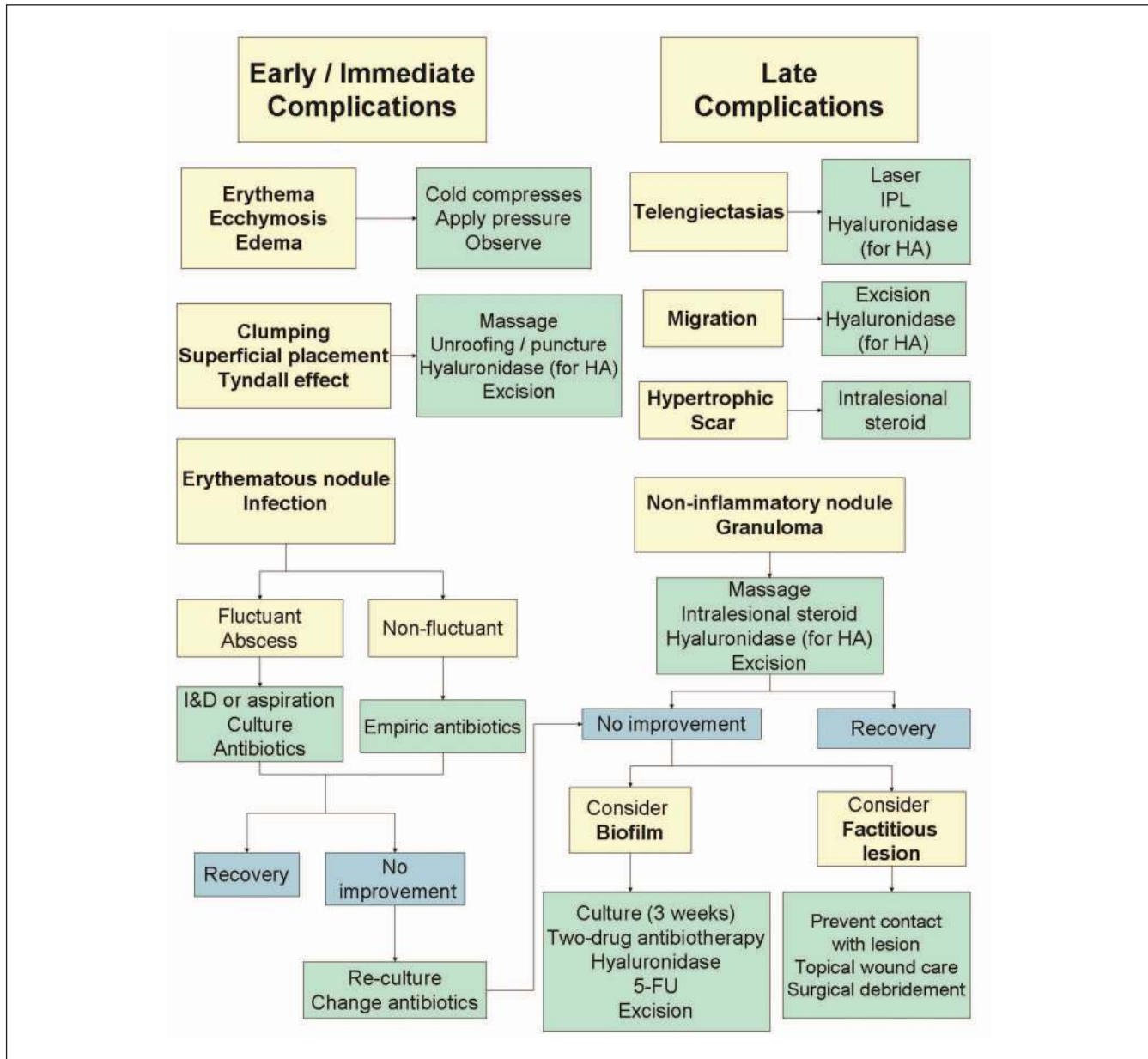


Figure 5. Algorithm for treatment of mild to moderate complications following filler injections. 5-FU, 5-fluorouracil; HA, hyaluronic acid; IPL, intense pulsed light; I&D, incision and drainage.

be stopped, and the area should be massaged and warm compresses applied to increase vasodilatation.^{53,58} Utilization of nitroglycerine paste and hyaluronidase also is advocated for early presenting cases. Other treatments include systemic or topical steroids to reduce associated inflammation, thereby mitigating the degree of injury.^{20,32,53,65} Although aspirin and IV prostaglandins have been suggested, their efficacy has not been proven.^{11,16,21,22} Other options with unproven efficacy are filler removal via puncture and low-molecular-weight heparin.^{11,20,27} Of course, patients with any vascular complication should remain under extremely close care. The

treatment measures are aimed at dissolving the product, facilitating blood flow, and promoting vasodilation. Dayan et al²⁰ have suggested the use of hyaluronidase in all cases of vascular compromise, independent of the filler type, due to its edema-reducing benefits and theoretical advantage in reducing occluding vessel pressure.

Although we were not able to correlate the time of therapy initiation with outcomes due to the insufficient data of case reports, it is well known that prompt intervention is crucial. In an experimental study, Kim et al¹⁰ found that the use of hyaluronidase within 4 hours of injection proved to be a successful salvage procedure for HA fillers.

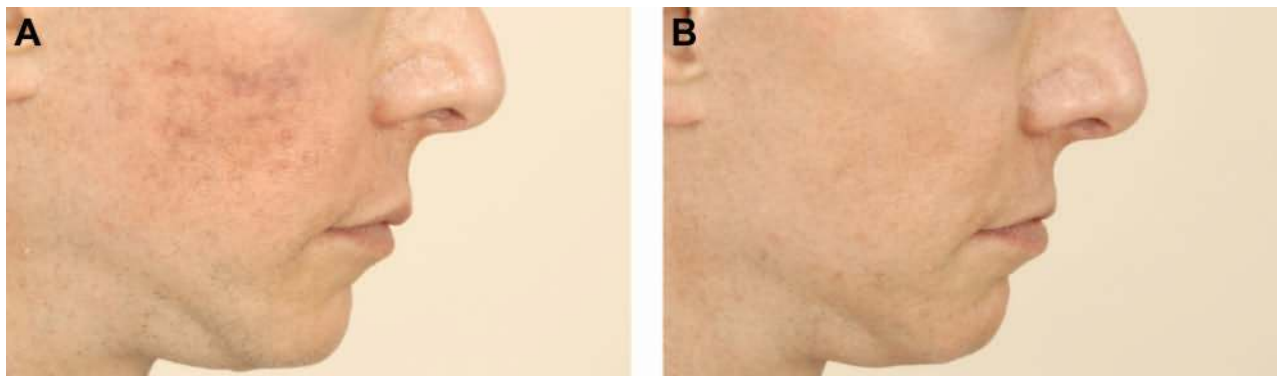


Figure 6. (A) This 62-year-old man had inadvertent intravascular injection of poly-L-lactic acid during treatment of the cheeks. Warm compresses were applied immediately. (B) Three months after injection. The patient recovered without any sequelae.



Figure 7. The use of a blunt-tip cannula during filler injection reduces the risk of intravascular penetration.

Once necrosis has occurred, debridement and wound care are required to minimize scarring. Typically, an eschar develops, which heals over several weeks by granulation and reepithelialization. The means of surgical reconstruction are site specific.

Vascular complications are best avoided with appropriate training and injection techniques. The most important controllable factor for practitioners is the speed of injection. Filler should be injected slowly and the needle withdrawn using the least amount of pressure.⁸⁶ Other precautions include aspiration before injection, delivery of material at different points, and injection of small volumes per pass.^{58,67,74,86,87} The use of small-caliber needles has been advocated by some since they slow the speed of injection.^{58,86} The use of blunt needles in high-risk regions such as the glabella, nose, and NLF is another means of reducing injury to vessels⁸⁸⁻⁹⁰ (Figure 7). The injection technique differs with blunt tips: there is less movement and less subcision and consequently less trauma.⁹⁰ However, these cannulae are prone to bend with multiple passes, and some planes may be difficult to breach with the blunt tip, resulting in excess accumulation of the product. Use of an epinephrine-containing product has inherent risks and benefits. Although it may mask a complication because of its blanching effect, it also may

decrease the chance of bruising by constricting the blood vessels.^{26,31}

Consensus treatment of suspected intravascular injection includes immediate cessation of the injection, massage, warm compresses, topical nitroglycerine paste, and hyaluronidase (regardless of filler type). Other suggestions (but without proven efficacy) include removal of filler via puncture, systemic or topical steroids, aspirin, low-molecular-weight heparin, and IV prostaglandins. An algorithm for the treatment of suspected intravascular injection is presented in Figure 8.

The underlying mechanism for visual impairment after facial injection is related to retrograde embolization from peripheral vessels into the ophthalmic arterial system.^{5,37-42,86,91} Intra-arterially injected material is displaced via a high injection pressure past the origin of the retinal artery, and when the plunger is released, it is propelled into this system. Even a very small amount of material can cause embolization of the retinal artery because it is an end artery with no physiologic anastomoses.^{86,92} The retina is also very sensitive to ischemia.^{86,92} Factors contributing to this phenomenon are high injection pressures, the distance between injection site and retinal circulation, and the amount of injected material.^{37,86}

If symptoms of visual impairment occur, the goal is to reduce intraocular pressure and dislodge the embolus to improve perfusion of the retina and optic nerve. There is no single reliable treatment for iatrogenic retinal artery embolism.⁸⁶ Recommended measures include immediate ophthalmologic consultation, ocular massage, timolol eye drops, diuretics, hemodilution (with hydroxyethyl starch), corticosteroids, calcium channel blockers, anticoagulation, and needle decompression of the anterior chamber.^{42,86,93} Other modalities that have been used after fat embolism to the retinal artery include carbon dioxide and oxygen therapy,⁹⁴ thrombolysis with urokinase,⁹⁵ and vasodilation.⁹⁶ However, attempts to reverse retinal artery occlusion are often unsuccessful. It is unclear whether the recovery is due to timely initiation of therapy, transient embolism, or favorable location of infarct in the retina. Unfortunately, in cases of vision loss, the outcome is grave regardless of the treatment rendered.

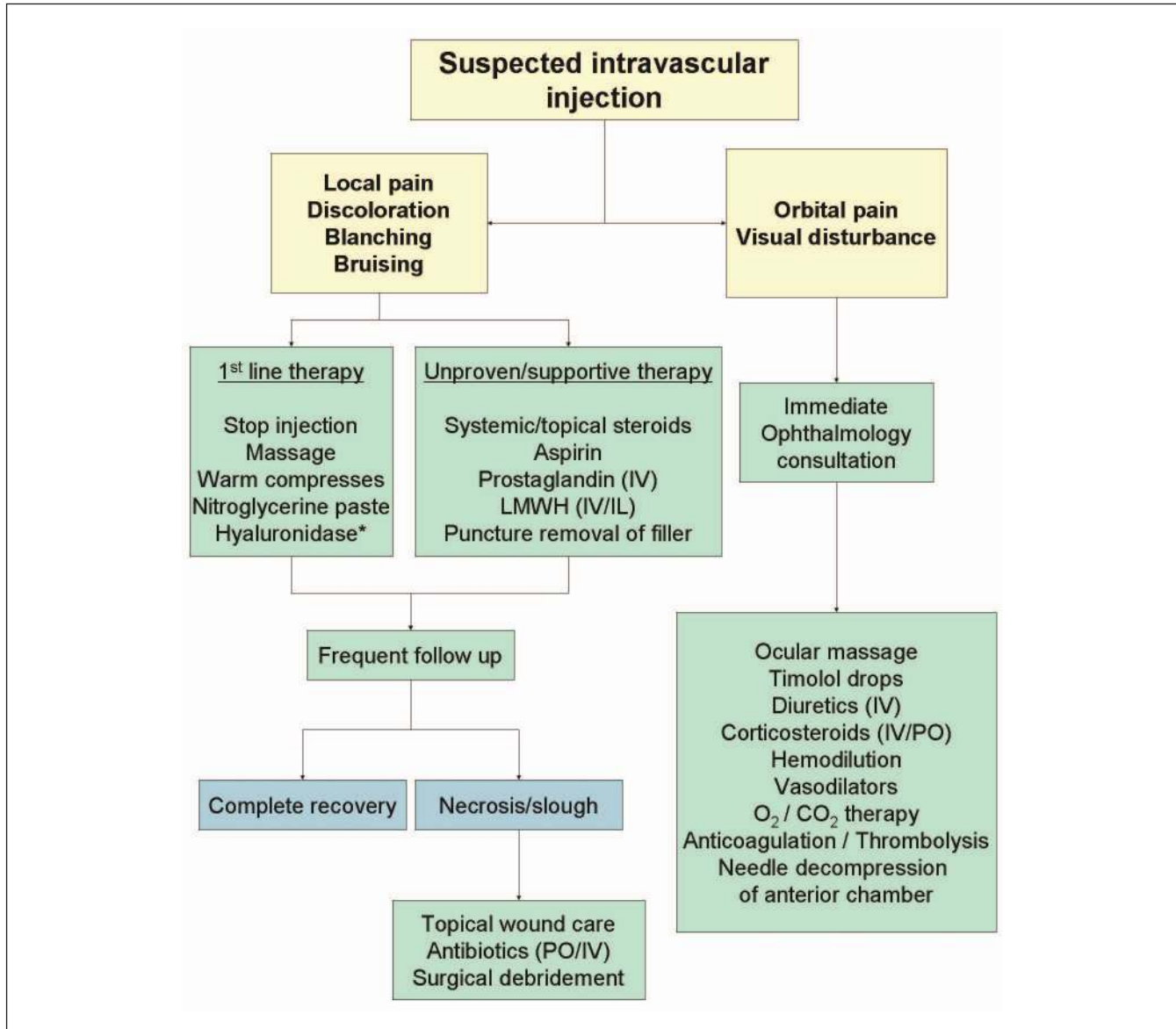


Figure 8. Algorithm for treatment of severe complications following filler injections. *Hyaluronidase is recommended independent of filler type. IL, intralesional; IV, intravenous; LMWH, low-molecular-weight heparin; PO, per oral.

CONCLUSIONS

The soft-tissue fillers approved for use in the United States have an excellent safety profile, which is reflected by their increasing use. Although serious complications are rare, they can occur. Whenever fillers are placed, the products needed to treat complications should be readily available. These should include, but not be limited to, hyaluronidase, nitroglycerine paste, and warm compresses. Physicians also should be aware of the high-risk regions of the midface, as identified in the present review. Injections to the nose, NLF, and glabella require additional caution.

Familiarity with the prevention, presentation, and immediate treatment of these rare events is essential for attaining the best possible outcome.

Disclosures

The authors declared no potential conflicts of interest with respect to the research, authorship, and publication of this article.

Funding

The authors received no financial support for the research, authorship, and publication of this article.

REFERENCES

1. American Society for Aesthetic Plastic Surgery. ASAPS National Cosmetic Surgery Databank Statistics 2012. <http://www.surgery.org/sites/default/files/ASAPS-2012-Stats.pdf>. Accessed May 6, 2013.
2. American Society for Dermatologic Surgery. <http://www.asds.net>. Accessed October 10, 2012.
3. de Melo Carpaneda E, Carpaneda CA. Adverse results with PMMA fillers. *Aesthetic Plast Surg*. 2012;36:955-963.
4. Park TH, Seo SW, Kim JK, et al. Clinical experience with hyaluronic acid–filler complications. *J Plast Reconstr Aesthetic Surg*. 2011;64:892-896.
5. Hwang YH, Hwang JH, Kim JS. Branch retinal artery occlusion after periocular dermal filler injection. *Retin Cases Brief Rep*. 2008;2:338-341.
6. Kang YS, Kim JW, Choi WS, et al. A case of sudden unilateral vision loss following injection of filler into the glabella. *Korean J Dermatol*. 2007;45:381-383.
7. Lemperle G, Romano JJ, Busso M. Soft tissue augmentation with Artecoll: 10-year history, indications, techniques, and complications. *Dermatol Surg*. 2003;29:573-587.
8. Grunebaum LD, Bogdan Allemann I, Dayan S, et al. The risk of alar necrosis associated with dermal filler injection. *Dermatol Surg*. 2009;35(suppl 2):1635-1640.
9. Humphrey CD, Arkins JP, Dayan SH. Soft tissue fillers in the nose. *Aesthetic Surg J*. 2009;29:477-484.
10. Kim DW, Yoon ES, Ji YH, et al. Vascular complications of hyaluronic acid fillers and the role of hyaluronidase in management. *J Plast Reconstr Aesthetic Surg*. 2011;64:1590-1595.
11. Kim SG, Kim YJ, Lee SI, et al. Salvage of nasal skin in a case of venous compromise after hyaluronic acid filler injection using prostaglandin E. *Dermatol Surg*. 2011;37:1817-1819.
12. Monheit G. Fibrel: soft tissue augmentation. In: Klein AW, ed. *Soft Tissue Augmentation in clinical practice: procedures and techniques*. New York, NY: Marcel Dekker; 1998:155-171.
13. Salles AG, Lotierzo PH, Gemperli R, et al. Complications after polymethylmethacrylate injections: report of 32 cases. *Plast Reconstr Surg*. 2008;121:1811-1820.
14. Sung HM, Suh IS, Lee HB, et al. Case reports of adipose-derived stem cell therapy for nasal skin necrosis after filler injection. *Arch Plast Surg*. 2011;39:51-54.
15. Winslow CP. The management of dermal filler complications. *Facial Plast Surg*. 2009;25:124-128.
16. Inoue K, Sato K, Matsumoto D, et al. Arterial embolization and skin necrosis of the nasal ala following injection of dermal fillers. *Plast Reconstr Surg*. 2008;121:127e-128e.
17. Georgescu D, Jones Y, McCann JD, et al. Skin necrosis after calcium hydroxylapatite injection into the glabellar and nasolabial folds. *Ophthal Plast Reconstr Surg*. 2009;25:498-499.
18. Burt B, Nakra T, Isaacs DK, et al. Alar necrosis after facial injection of hyaluronic acid. *Plast Reconstr Surg*. 2010;125:199e-200e.
19. Bellman B. Complication following suspected intra-arterial injection of Restylane. *Aesthetic Surg J*. 2006;26:304-305.
20. Dayan SH, Arkins JP, Mathison CC. Management of impending necrosis associated with soft tissue filler injections. *J Drugs Dermatol*. 2011;10:1007-1012.
21. Hirsch RJ, Lupo M, Cohen JL, et al. Delayed presentation of impending necrosis following soft tissue augmentation with hyaluronic acid and successful management with hyaluronidase. *J Drugs Dermatol*. 2007;6:325-328.
22. Hirsch RJ, Cohen JL, Carruthers JD. Successful management of an unusual presentation of impending necrosis following a hyaluronic acid injection embolus and a proposed algorithm for management with hyaluronidase. *Dermatol Surg*. 2007;33:357-360.
23. Park KY, Son IP, Li K, et al. Reticulated erythema after nasolabial fold injection with hyaluronic acid: the importance of immediate attention. *Dermatol Surg*. 2011;37:1697-1699.
24. Friedman PM, Mafong EA, Kauvar AN, et al. Safety data of injectable nonanimal stabilized hyaluronic acid gel for soft tissue augmentation. *Dermatol Surg*. 2002;28:491-494.
25. Steinsapir KD, Steinsapir SM. Deep-fill hyaluronic acid for the temporary treatment of the naso-jugal groove: a report of 303 consecutive treatments. *Ophthal Plast Reconstr Surg*. 2006;22:344-348.
26. Gladstone HB, Cohen JL. Adverse effects when injecting facial fillers. *Semin Cutan Med Surg*. 2007;26:34-39.
27. Schanz S, Schippert W, Ulmer A, et al. Arterial embolization caused by injection of hyaluronic acid (Restylane). *Br J Dermatol*. 2002;146:928-929.
28. Bachmann F, Erdmann R, Hartmann V, et al. The spectrum of adverse reactions after treatment with injectable fillers in the glabellar region: results from the Injectable Filler Safety Study. *Dermatol Surg*. 2009;35(suppl 2):1629-1634.
29. Hanke CW, Higley HR, Jolivet DM, et al. Abscess formation and local necrosis after treatment with Zyderm or Zyplast collagen implant. *J Am Acad Dermatol*. 1991;25:319-326.
30. Nettare K, Maas C. Facial filler and neurotoxin complications. *Facial Plast Surg*. 2012;28:288-293.
31. Kassir R, Kolluru A, Kassir M. Extensive necrosis after injection of hyaluronic acid filler: case report and review of the literature. *J Cosmet Dermatol*. 2011;10:224-231.
32. Narins RS, Jewell M, Rubin M, et al. Clinical conference: management of rare events following dermal fillers—focal necrosis and angry red bumps. *Dermatol Surg*. 2006;32:426-434.
33. Lowe NJ. Arterial embolization caused by injection of hyaluronic acid (Restylane). *Br J Dermatol*. 2003;148:379-380.
34. Castillo GD. Management of blindness in the practice of cosmetic surgery. *Otolaryngol Head Neck Surg*. 1989;100:559-562.
35. Peter S, Mennel S. Retinal branch artery occlusion following injection of hyaluronic acid (Restylane). *Clin Experiment Ophthalmol*. 2006;34:363-364.
36. Apte RS, Solomon SD, Gehlbach P. Acute choroidal infarction following subcutaneous injection of micronized

- dermal matrix in the forehead region. *Retina*. 2003;23:552-554.
37. Kim YJ, Kim SS, Song WK, et al. Ocular ischemia with hypotony after injection of hyaluronic acid gel. *Ophthalmol Plast Reconstr Surg*. 2011;27:e152-e155.
 38. Kubota T, Hirose H. Permanent loss of vision following cosmetic rhinoplastic surgery. *Jpn J Ophthalmol*. 2005;49:535-536.
 39. Roberts SA, Arthurs BP. Severe visual loss and orbital infarction following periorbital aesthetic poly-(L)-lactic acid (PLLA) injection. *Ophthalmol Plast Reconstr Surg*. 2012;28:e68-e70.
 40. Silva MT, Curi AL. Blindness and total ophthalmoplegia after aesthetic polymethylmethacrylate injection: case report. *Arq Neuropsiquiatr*. 2004;62:873-874.
 41. Sung MS, Kim HG, Woo KI, et al. Ocular ischemia and ischemic oculomotor nerve palsy after vascular embolization of injectable calcium hydroxylapatite filler. *Ophthalmol Plast Reconstr Surg*. 2010;26:289-291.
 42. Kwon DY, Park MH, Koh SB, et al. Multiple arterial embolism after illicit intranasal injection of collagenous material. *Dermatol Surg*. 2010;36:1196-1199.
 43. Hanke WC. Adverse reactions to bovine collagen. In: Klein AW, ed. *Soft Tissue Augmentation in Clinical Practice: Procedures and Techniques*. New York, NY: Marcel Dekker; 1998:145.
 44. Smith S, Busso M, McClaren M, et al. A randomized, bilateral, prospective comparison of calcium hydroxylapatite microspheres versus human-based collagen for the correction of nasolabial folds. *Dermatol Surg*. 2007;33(suppl 2):S112-S121.
 45. Lindqvist C, Tveten S, Bondevik BE, et al. A randomized, evaluator-blind, multicenter comparison of the efficacy and tolerability of Perlane versus Zyplast in the correction of nasolabial folds. *Plast Reconstr Surg*. 2005;115:282-289.
 46. Sclafani AP, Romo T III, Parker A, et al. Homologous collagen dispersion (Dermalogen) as a dermal filler: persistence and histology compared with bovine collagen. *Ann Plast Surg*. 2002;49:181-188.
 47. Narins RS, Brandt F, Leyden J, et al. A randomized, double-blind, multicenter comparison of the efficacy and tolerability of Restylane versus Zyplast for the correction of nasolabial folds. *Dermatol Surg*. 2003;29:588-595.
 48. Carruthers A, Carruthers J. Non-animal-based hyaluronic acid fillers: scientific and technical considerations. *Plast Reconstr Surg*. 2007;120:33S-40S.
 49. Narins RS, Dayan SH, Brandt FS, et al. Persistence and improvement of nasolabial fold correction with nonanimal-stabilized hyaluronic acid 100,000 gel particles/mL filler on two retreatment schedules: results up to 18 months on two retreatment schedules. *Dermatol Surg*. 2008;34(suppl 1):S2-S8.
 50. Smith SR, Jones D, Thomas JA, et al. Duration of wrinkle correction following repeat treatment with Juvederm hyaluronic acid fillers. *Arch Dermatol Res*. 2010;302:757-762.
 51. Narins RS, Coleman WP III, Donofrio LM, et al. Improvement in nasolabial folds with a hyaluronic acid filler using a cohesive polydensified matrix technology: results from an 18-month open-label extension trial. *Dermatol Surg*. 2010;36(suppl 3):1800-1808.
 52. US Food and Drug Administration. <http://www.fda.gov/ohrms/dockets/ac/08/briefing/2008-4391b1-01%20-%20FDA%20Executive%20Summary%20Dermal%20Fillers.pdf>. Accessed October 10, 2012.
 53. De Boule K. Management of complications after implantation of fillers. *J Cosmet Dermatol*. 2004;3:2-15.
 54. Jones D. Volumizing the face with soft tissue fillers. *Clin Plast Surg*. 2011;38:379-390, v.
 55. Rohrich RJ, Monheit G, Nguyen AT, et al. Soft-tissue filler complications: the important role of biofilms. *Plast Reconstr Surg*. 2010;125:1250-1256.
 56. Lemperle G, Rullan PP, Gauthier-Hazan N. Avoiding and treating dermal filler complications. *Plast Reconstr Surg*. 2006;118:92S-107S.
 57. Lemperle G, Duffy DM. Treatment options for dermal filler complications. *Aesthetic Surg J*. 2006;26:356-364.
 58. Sclafani AP, Fagien S. Treatment of injectable soft tissue filler complications. *Dermatol Surg*. 2009;35(suppl 2):1672-1680.
 59. Requena L, Requena C, Christensen L, et al. Adverse reactions to injectable soft tissue fillers. *J Am Acad Dermatol*. 2010;64:1-34; quiz 35-36.
 60. Alam M, Gladstone H, Kramer EM, et al. ASDS guidelines of care: injectable fillers. *Dermatol Surg*. 2008;34(suppl 1):S115-S148.
 61. Wesley NO, Dover JS. The filler revolution: a six-year retrospective. *J Drugs Dermatol*. 2009;8:903-907.
 62. Kanchwala SK, Holloway L, Bucky LP. Reliable soft tissue augmentation: a clinical comparison of injectable soft-tissue fillers for facial-volume augmentation. *Ann Plast Surg*. 2005;55:30-35.
 63. Leonhardt JM, Lawrence N, Narins RS. Angioedema acute hypersensitivity reaction to injectable hyaluronic acid. *Dermatol Surg*. 2005;31:577-579.
 64. Morley AM, Malhotra R. Use of hyaluronic acid filler for tear-trough rejuvenation as an alternative to lower eyelid surgery. *Ophthalmol Plast Reconstr Surg*. 2011;27:69-73.
 65. Alam M, Dover JS. Management of complications and sequelae with temporary injectable fillers. *Plast Reconstr Surg*. 2007;120:98S-105S.
 66. Graivier MH, Bass LS, Busso M, et al. Calcium hydroxylapatite (Radiesse) for correction of the mid- and lower face: consensus recommendations. *Plast Reconstr Surg*. 2007;120:55S-66S.
 67. Cohen JL. Understanding, avoiding, and managing dermal filler complications. *Dermatol Surg*. 2008;34(suppl 1):S92-S99.
 68. Beer KR. Radiesse nodule of the lips from a distant injection site: report of a case and consideration of etiology and management. *J Drugs Dermatol*. 2007;6:846-847.
 69. Sadick NS, Katz BE, Roy D. A multicenter, 47-month study of safety and efficacy of calcium hydroxylapatite for soft tissue augmentation of nasolabial folds and other areas of the face. *Dermatol Surg*. 2007;33(suppl 2):S122-S127.
 70. Berlin A, Cohen JL, Goldberg DJ. Calcium hydroxylapatite for facial rejuvenation. *Semin Cutan Med Surg*. 2006;25:132-137.

71. Christensen L, Breiting V, Janssen M, et al. Adverse reactions to injectable soft tissue permanent fillers. *Aesthetic Plast Surg*. 2005;29:34-48.
72. Lemperle G, Gauthier-Hazan N, Wolters M, et al. Foreign body granulomas after all injectable dermal fillers, part 1: possible causes. *Plast Reconstr Surg*. 2009;123:1842-1863.
73. Bentkover SH. The biology of facial fillers. *Facial Plast Surg*. 2009;25:73-85.
74. Bailey SH, Cohen JL, Kenkel JM. Etiology, prevention, and treatment of dermal filler complications. *Aesthetic Surg J*. 2011;31:110-121.
75. Dayan SH, Arkins JP, Brindise R. Soft tissue fillers and biofilms. *Facial Plast Surg*. 2011;27:23-28.
76. Narins RS, Coleman WP III, Glogau RG. Recommendations and treatment options for nodules and other filler complications. *Dermatol Surg*. 2009;35(suppl 2):1667-1671.
77. Bjarnsholt T, Tolker-Nielsen T, Givskov M, et al. Detection of bacteria by fluorescence in situ hybridization in culture-negative soft tissue filler lesions. *Dermatol Surg*. 2009;35(suppl 2):1620-1624.
78. Marusza W, Mlynarczyk G, Olszanski R, et al. Probable biofilm formation in the cheek as a complication of soft tissue filler resulting from improper endodontic treatment of tooth 16. *Int J Nanomedicine*. 2012;7:1441-1447.
79. Christensen L. Normal and pathologic tissue reactions to soft tissue gel fillers. *Dermatol Surg*. 2007;33(suppl 2):S168-S175.
80. Pecharki D, Petersen FC, Scheie AA. Role of hyaluronidase in *Streptococcus intermedius* biofilm. *Microbiology*. 2008;154:932-938.
81. Attila C, Ueda A, Wood TK. 5-Fluorouracil reduces biofilm formation in *Escherichia coli* K-12 through global regulator AriR as an antivirulence compound. *Appl Microbiol Biotechnol*. 2009;82:525-533.
82. Nyhlen A, Ljungberg B, Nilsson-Ehle I, et al. Bactericidal effect of combinations of antibiotic and antineoplastic agents against *Staphylococcus aureus* and *Escherichia coli*. *Chemotherapy*. 2002;48:71-77.
83. Cassuto D, Marangoni O, De Santis G, et al. Advanced laser techniques for filler-induced complications. *Dermatol Surg*. 2009;35(suppl 2):1689-1695.
84. Moskowitz SM, Foster JM, Emerson J, et al. Clinically feasible biofilm susceptibility assay for isolates of *Pseudomonas aeruginosa* from patients with cystic fibrosis. *J Clin Microbiol*. 2004;42:1915-1922.
85. Arron ST, Neuhaus IM. Persistent delayed-type hypersensitivity reaction to injectable non-animal-stabilized hyaluronic acid. *J Cosmet Dermatol*. 2007;6:167-171.
86. Lazzeri D, Agostini T, Figus M, et al. Blindness following cosmetic injections of the face. *Plast Reconstr Surg*. 2012;129:995-1012.
87. Glaich AS, Cohen JL, Goldberg LH. Injection necrosis of the glabella: protocol for prevention and treatment after use of dermal fillers. *Dermatol Surg*. 2006;32:276-281.
88. Cohen JL. Utilizing blunt-tipped cannulas in specific regions for soft-tissue augmentation. *J Drugs Dermatol*. 2012;11:40-41.
89. Hexsel D, Soirefmann M, Porto MD, et al. Double-blind, randomized, controlled clinical trial to compare safety and efficacy of a metallic cannula with that of a standard needle for soft tissue augmentation of the nasolabial folds. *Dermatol Surg*. 2012;38:207-214.
90. Cassuto D. Blunt-tipped microcannulas for filler injection: an ethical duty? *J Drugs Dermatol*. 2012;11:41.
91. Coleman SR. Avoidance of arterial occlusion from injection of soft tissue fillers. *Aesthetic Surg J*. 2002;22:555-557.
92. Duker J. Retinal arterial obstruction. In: Yanoff M, Duker JS, eds. *Ophthalmology*. 2nd ed. St Louis, MO: Mosby; 2004:854-861.
93. Schumacher M, Schmidt D, Jurklics B, et al. Central retinal artery occlusion: local intra-arterial fibrinolysis versus conservative treatment, a multicenter randomized trial. *Ophthalmology*. 2010;117:1367-1375.e1.
94. Lee DH, Yang HN, Kim JC, et al. Sudden unilateral visual loss and brain infarction after autologous fat injection into nasolabial groove. *Br J Ophthalmol*. 1996;80:1026-1027.
95. Park SJ, Woo SJ, Park KH, et al. Partial recovery after intraarterial pharmacomechanical thrombolysis in ophthalmic artery occlusion following nasal autologous fat injection. *J Vasc Interv Radiol*. 2011;22:251-254.
96. Shin H, Lemke BN, Stevens TS, et al. Posterior ciliary-artery occlusion after subcutaneous silicone-oil injection. *Ann Ophthalmol*. 1988;20:342-344.